

# **Influence of the Choice of Transplant Material for Stabilization of the Cervical Spine on The Reduction of Stay in Hospital**

Mamadaliyev Abbosbek Bakhtiyarovich

PhD, Assistant of the Department of Traumatology, Orthopedics and Neurosurgery of Andijan State Medical Institute

Eranov Sherzod Nuraliyevich

PhD, Assistant of the Department of Traumatology and Orthopedics of Samarkand State Medical University

Tokhirova Zebuniso Shukhratjonovna

Student of Master-Degree of the Department of Traumatology, Orthopedics and Neurosurgery of Andijan State Medical Institute

## **Abstract:**

We conducted a particular study, the aim of which was to determine the optimal method of surgical stabilization of the cervical spine in trauma and degenerative diseases. In determining the choice of method, we were guided not only the reliability and availability of the method, but also for early activation of patients in the postoperative period.

**Keywords:** biocompatibility, implants, cervical instability, cervical stabilization, anterior stabilization, average length of hospital stay.

## **Introduction**

### **Relevance of the topic**

Complicated pathology of the cervical spine, caused by trauma or degenerative-dystrophic lesions, is one of the most severe types of pathology. Lesions of the cervical spinal cord that occur with this type of pathology lead to the appearance of a complex set of structural and functional changes, manifested in the form of a gross neurological deficit, various neurotrophic, metabolic, dyscirculatory disorders and infectious complications, which significantly aggravate the course of the pathological process [3, 6]. Known methods of conservative therapy for this pathology rarely lead to positive results, are accompanied by a large number of complications, high mortality and disability of patients [4]. The most significant factor that positively affects the immediate and long-term outcomes of treatment in this group of patients is timely, adequate surgical intervention [1,7].

---

The need to perform surgical approaches for anterior compression of the cervical spinal cord in the vast majority of cases is beyond doubt [2].

Difficulties in reliable stabilization of the cervical spine, due to the anatomical and physiological features of the structure and the high functional load of this region, have led to the creation of a large number of materials and structures currently used for these purposes, which indicates the unresolved problem [5]

Purpose of the study. Improving the efficiency of anterior stabilization of the cervical spine by optimizing anterior interbody fusion based on the use of titanium nickelide implants of various designs.

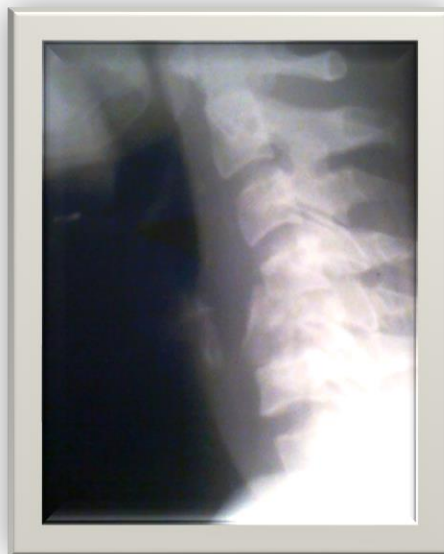Material and research methods. In the present study, 34 patients who were operated on for spinal cord injury - 21 (59.8%) and degenerative-dystrophic lesions - 13 (40.2%) were subjected to study and analysis. The patients were examined and treated at the clinic of the Andijan branch of Republican scientific center of emergency medicine in the period from 2020 to 2023

The patients were conditionally divided into three groups.

The first group of patients who underwent ventral stabilization of the cervical spine using a carbon implant included 24 patients. The causes of damage to the cervical spine in 14 patients were trauma, in 10 degenerative-dystrophic changes.

The second group included 6 patients who underwent ventral stabilization of the cervical spine using static implants made of porous titanium nickelide. The causes of damage to the cervical spine in 4 patients were trauma, in 2 degenerative-dystrophic changes.

The third group included 4 patients with discogenic cervical myeloradiculopathy, who received layered-porous titanium nickelide implants for anterior stabilization.



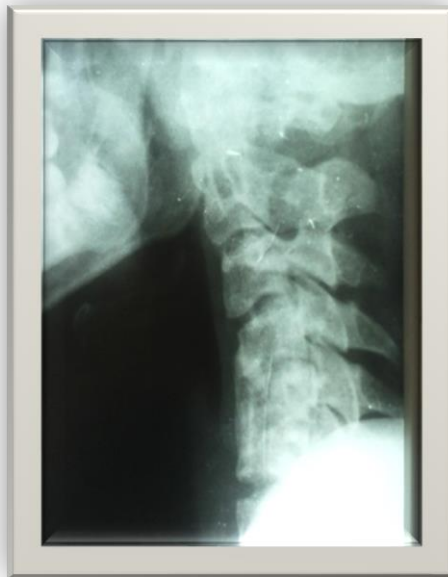
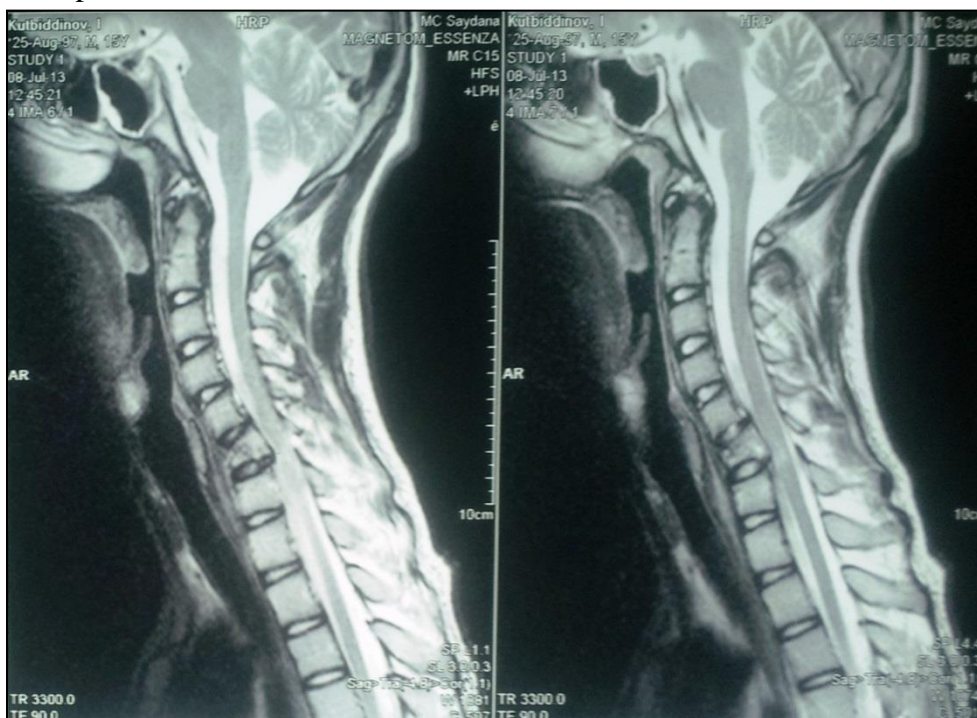


Figure 1. Patient M. - an operation was performed “open reduction of dislocation of the C5 vertebra. Resection of the C5 vertebral body and anterior stabilization with a carbon implant»



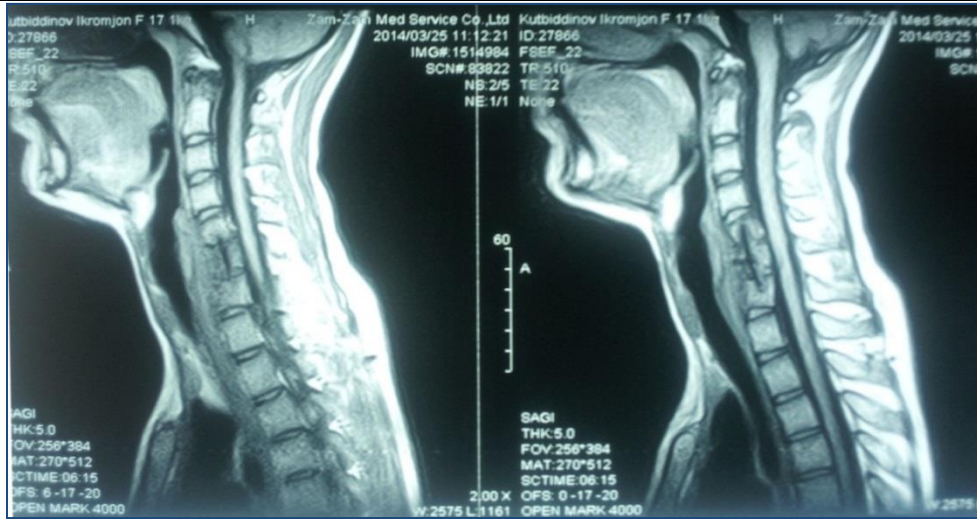


Figure 2. Patient K. - condition before and after the operation “Open reduction of dislocation C6. Resection of the C6 vertebral body. Anterior spinal fusion of C5-C7 vertebrae with a carbon implant»

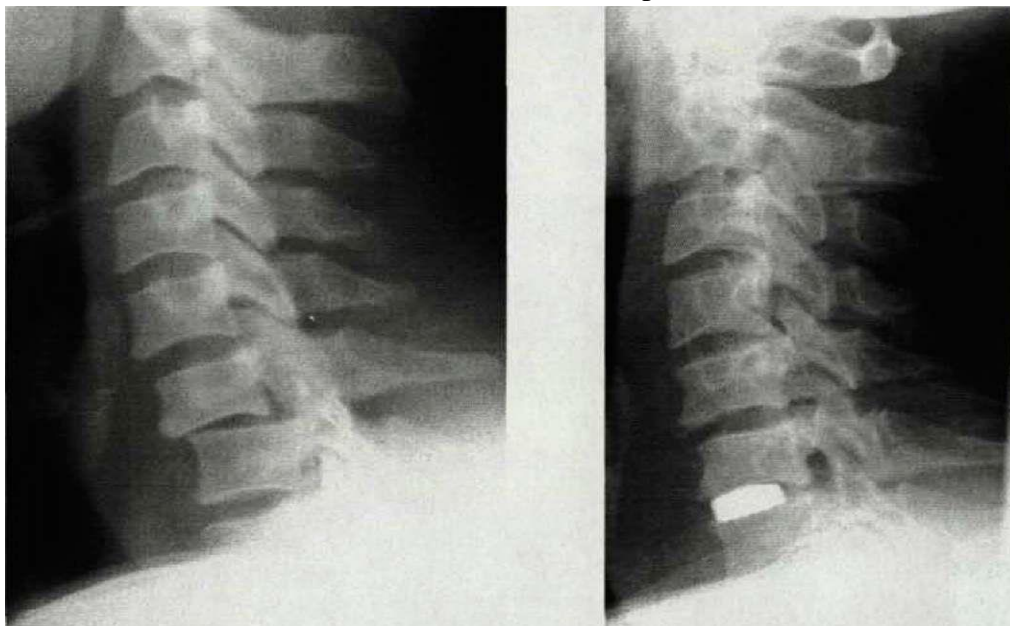


Figure 3. Patient P. Diagnosis: complicated dislocation of the C6 vertebral body. Operation: “Open reduction of dislocation of C6 vertebra. Anterior discectomy. Fixation with a dynamic titanium implant»

### **Results of the study and their discussion**

When evaluating the data of the study, during which satisfactory and good results were obtained in patients of all three groups, we relied on the timing of discharge from the hospital.

Table 1. Length of stay in the hospital for patients with degenerative-dystrophic lesions of the cervical spine depending on the method of anterior stabilization

Stabilization method	Number of patients	Average length of hospital stay (days)
Spinal fusion with carbon implants	24	32,3
Spinal fusion with static titanium implants	6	21,4
Spinal fusion with dynamic titanium implants	4	14,3

### Conclusion

Thus, anterior fusion with static titanium nickelide implants in patients with complicated trauma of the cervical spine provides sufficiently reliable stabilization of the spinal segment, does not require additional external immobilization, facilitates rehabilitation measures in the early postoperative period, and reduces the length of stay of patients in the hospital by 1.5 times.

### Used Literature

1. Bachhuber A. Frakturen der Halswirbelsäule und Bandscheibenläsionen [Cervical fractures and disc lesions]. *Radiologe*. 2021 Aug;61(8):714-719. German. doi: 10.1007/s00117-021-00880-w.
2. Barsa P, Fröhlich R, Adamík J, Suchomel P. Surgical treatment of cervical spine fractures in ankylosing spondylitis patients: posterior stabilization using intraoperative CT scanner-based navigation. *Rozhl Chir*. 2020 Spring;99(5):212-218. English. doi: 10.33699/PIS.2020.99.5.212-218.
3. Fakhoury J, Dowling TJ. Cervical Degenerative Disc Disease. 2022 Aug 22. In: *StatPearls* [Internet]. Treasure Island (FL): StatPearls Publishing; 2022 Jan–.
4. Liao S, Jung MK, Hörnig L, Grützner PA, Kreinest M. Injuries of the upper cervical spine-how can instability be identified? *Int Orthop*. 2020 Jul;44(7):1239-1253. doi: 10.1007/s00264-020-04593-y. Epub 2020 May 25.
5. Maschmann C, Jeppesen E, Rubin MA, Barfod C. New clinical guidelines on the spinal stabilisation of adult trauma patients - consensus and evidence based. *Scand J Trauma Resusc Emerg Med*. 2019 Aug 19;27(1):77. doi: 10.1186/s13049-019-0655-x.
6. Petrone B, Dowling TJ. Cervical Dislocation. 2022 May 23. In: *StatPearls* [Internet]. Treasure Island (FL): StatPearls Publishing;
7. Shlobin NA, Dahdaleh NS. Surgical Stabilization of a Cervical Fracture in a Patient with Ankylosing Spondylitis in the Sitting Position. *Cureus*. 2020 Jan 10;12(1):e6625. doi: 10.7759/cureus.6625.